

EDITORIAL COMMENT

Electrocardiographic Diagnosis of Life-Threatening STEMI Equivalents



When Every Minute Counts*

Babken Asatryan, MD, PhD, Lukas Vaisnora, MD, Negar Manavifar, MD

Despite enormous efforts implemented in the early detection and timely treatment of acute coronary syndromes, acute myocardial infarction continues to be the most common cause of death worldwide (1). Prompt diagnosis of acute coronary occlusion and early reperfusion therapy are essential to reduce the morbidity and mortality in patients with ST-segment elevation myocardial infarction (STEMI) (2). In practice, however, the full spectrum of electrocardiography (ECG) abnormalities indicating acute coronary ischemia or occlusion requiring immediate cardiac catheterization go beyond the well-known ST-segment elevation pattern.

SEE PAGE 663

In this issue of *JACC: Case Reports*, Plane et al. (3) describe the clinical case of a 48-year-old man admitted with out-of-hospital cardiac arrest. After successful resuscitation, the patient reported chest pain, and the ECG showed upsloping ST-segment depression (>1 mm) at the J-point, followed by tall, symmetrical T waves in precordial leads, consistent with the de Winter syndrome. Emergency coronary catheterization revealed an acute thrombotic occlusion of the proximal left anterior descending coronary artery. This case illustrates the importance of early recognition of the de Winter ECG pattern to initiate the essential coronary catheterization.

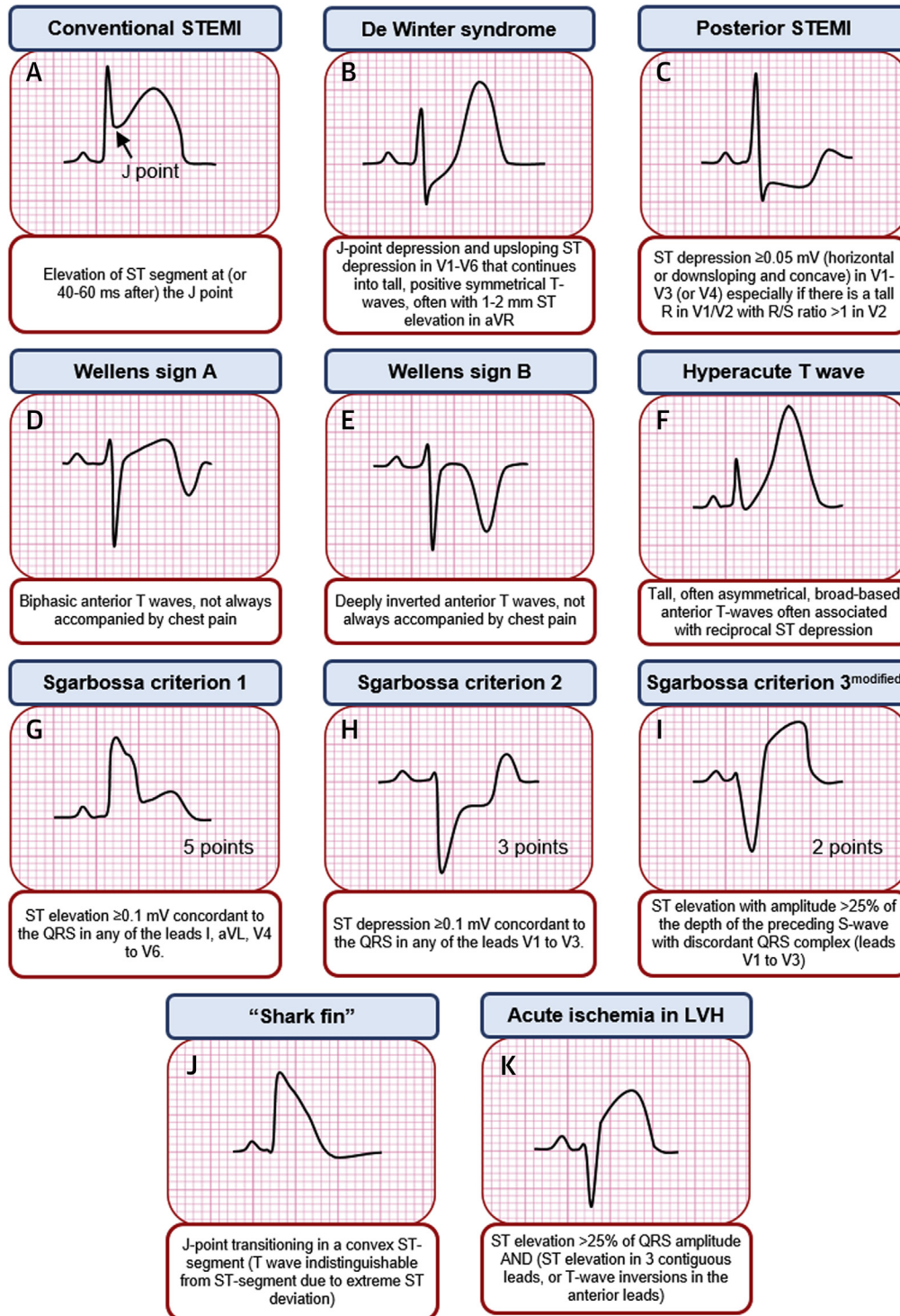
Several high-risk ECG patterns have been reported in association with acute myocardial ischemia due to critical stenosis or occlusion of a coronary artery. These patterns include the de Winter syndrome pattern (4); isolated posterior STEMI, a challenge to diagnose with a 12-lead ECG but easy to recognize with additional posterior leads V_7 to V_9 ; Wellens syndrome with often evolving T-wave abnormality (signs A and B) (5); the hyperacute T waves, usually preceding recognizable ST-segment elevation; and the “shark fin” sign (Figure 1). Furthermore, ECG criteria have been proposed to identify acute myocardial infarction with moderate-to-high probability in patients with pre-existing conditions that alter the QRS amplitude and width, as well as the J-point and/or ST-segment on resting ECG, such as left bundle branch block (LBBB) (6,7), right ventricular paced rhythm (8), and left ventricular hypertrophy. Integration of clinical evaluation along with serial ECGs, including assessment of previous ECGs recorded at an asymptomatic state, often assists in optimal decision making.

As primary percutaneous intervention (PCI) has been rapidly adopted as the default reperfusion strategy for STEMI worldwide, clearly defined criteria are essential for accurate diagnosis and timely referral of patients. In current practice, ST-segment elevation at the J-point, ≥ 1 mm in ≥ 2 adjacent leads (other than leads V_2 and V_3 , where elevation of ≥ 2 mm in men or ≥ 1.5 mm in women is considered significant) or a new LBBB is commonly used for STEMI diagnosis (2). However, these general ECG criteria fail to identify the STEMI equivalents. Therefore, patients with STEMI equivalents who do not present with these typical ECG changes despite having an acutely occluded coronary artery are more likely to undergo a delayed revascularization

*Editorials published in *JACC: Case Reports* reflect the views of the authors and do not necessarily represent the views of *JACC: Case Reports* or the American College of Cardiology.

From the Department of Cardiology, Inselspital, Bern University Hospital, Bern, Switzerland. The authors have reported that they have no relationships relevant to the contents of this paper to disclose.

FIGURE 1 ECG Patterns Hinting for Potentially High-Risk Critical Coronary Artery Stenosis or Occlusion



(A) Conventional STEMI. (B to K) Potential STEMI equivalents. (I) Modification of the Sgarbossa criterion 3 by Smith et al. (7) improved the test performance. According to the Smith-modified Sgarbossa rule, in the setting of a left bundle branch block or ventricular paced rhythm, a cutoff value of ≥ 3 points with the 3 criteria (G to I) has 91% sensitivity and 90% specificity for STEMI. ECG = electrocardiography; LVH = left ventricular hypertrophy; STEMI = ST-segment elevation myocardial infarction.

treatment. Thus, due to this under-recognition and lack of timely management, they often experience a worse clinical outcome and poor prognosis (9,10).

Although clinicians caring for patients presenting with chest pain rely upon ECG findings as the essential noninvasive test for identifying those who might benefit from primary PCI, their awareness of these high-risk ECG patterns are pivotal in early recognition to provide adequate treatment. However, currently, the STEMI equivalents are neither adequately covered in teaching curricula nor properly addressed by the current guidelines (11).

The authors certainly acknowledge that the ECG by itself is often insufficient to diagnose acute myocardial ischemia or infarction and that all ECG findings should be interpreted in the setting of clinical presentation (12). However, it must be emphasized that,

as not all ST-segment elevation patterns represent a “true STEMI” (e.g., previous myocardial infarction, left ventricular hypertrophy, Takotsubo cardiomyopathy), not all acute coronary occlusions needing primary PCI manifest the typical ST-segment elevation. Fine-tuning our recognition of this wide range of ECG patterns, hinting for potentially life-threatening coronary stenosis or occlusion, may allow faster diagnosis, resulting in proper treatment and improved patient outcomes.

ADDRESS FOR CORRESPONDENCE: Dr. Babken Asatryan, Department of Cardiology, Inselspital, Bern University Hospital, Freiburgstrasse 10, 3010 Bern, Switzerland. E-mail: babken.asatryan@insel.ch. Twitter: [@BabkenAsatryan](https://twitter.com/BabkenAsatryan).

REFERENCES

1. Benjamin EJ, Muntner P, Alonso A, et al. Heart disease and stroke statistics-2019 update: a report from the American Heart Association. *Circulation* 2019;139:e56-528.
2. O’Gara PT, Kushner FG, Ascheim DD, et al. 2013 ACCF/AHA guideline for the management of ST-elevation myocardial infarction: executive summary: a report of the American College of Cardiology Foundation/American Heart Association Task Force on Practice Guidelines. *J Am Coll Cardiol* 2013;61:485-510.
3. Plane AF, Valette X, Blanchart K, Ardouin P, Beygui F, Roule V. Occluded or not? A subtle Electrocardiographic answer. *J Am Coll Cardiol Case Rep* 2019;1:663-5.
4. de Winter RJ, Verouden NJ, Wellens HJ, Wilde AA. Interventional cardiology group of the Academic Medical C. A new ECG sign of proximal LAD occlusion. *N Engl J Med* 2008; 359:2071-3.
5. de Zwaan C, Bar FW, Wellens HJ. Characteristic electrocardiographic pattern indicating a critical stenosis high in left anterior descending coronary artery in patients admitted because of impending myocardial infarction. *Am Heart J* 1982;103: 730-6.
6. Sgarbossa EB, Pinski SL, Barbagelata A, et al. Electrocardiographic diagnosis of evolving acute myocardial infarction in the presence of left bundle-branch block. GUSTO-1 (Global Utilization of Streptokinase and Tissue Plasminogen Activator for Occluded Coronary Arteries) investigators. *N Engl J Med* 1996;334:481-7.
7. Smith SW, Dodd KW, Henry TD, Dvorak DM, Pearce LA. Diagnosis of ST-elevation myocardial infarction in the presence of left bundle branch block with the ST-elevation to S-wave ratio in a modified Sgarbossa rule. *Ann Emerg Med* 2012; 60:766-76.
8. Sgarbossa EB, Pinski SL, Gates KB, Wagner GS. Early electrocardiographic diagnosis of acute myocardial infarction in the presence of ventricular paced rhythm. GUSTO-I investigators. *Am J Cardiol* 1996;77:423-4.
9. Pride YB, Tung P, Mohanavelu S, et al. Angiographic and clinical outcomes among patients with acute coronary syndromes presenting with isolated anterior ST-segment depression: a TRITON-TIMI 38 (Trial to Assess Improvement in Therapeutic Outcomes by Optimizing Platelet Inhibition With Prasugrel-Thrombolysis In Myocardial Infarction 38) substudy. *J Am Coll Cardiol Intv* 2010;3:806-11.
10. Daly M, Finlay D, Guldenring D, et al. Detection of acute coronary occlusion in patients with acute coronary syndromes presenting with isolated ST-segment depression. *Eur Heart J Acute Cardiovasc Care* 2012;1:128-35.
11. Rokos IC, French WJ, Mattu A, et al. Appropriate cardiac cath lab activation: optimizing electrocardiogram interpretation and clinical decision-making for acute ST-elevation myocardial infarction. *Am Heart J* 2010;160:995-1003.
12. Thygesen K, Alpert JS, Jaffe AS, et al. Fourth universal definition of myocardial infarction (2018). *J Am Coll Cardiol* 2018;72:2231-64.

KEY WORDS acute coronary syndrome, electrocardiogram, myocardial infarction, myocardial ischemia, percutaneous coronary intervention